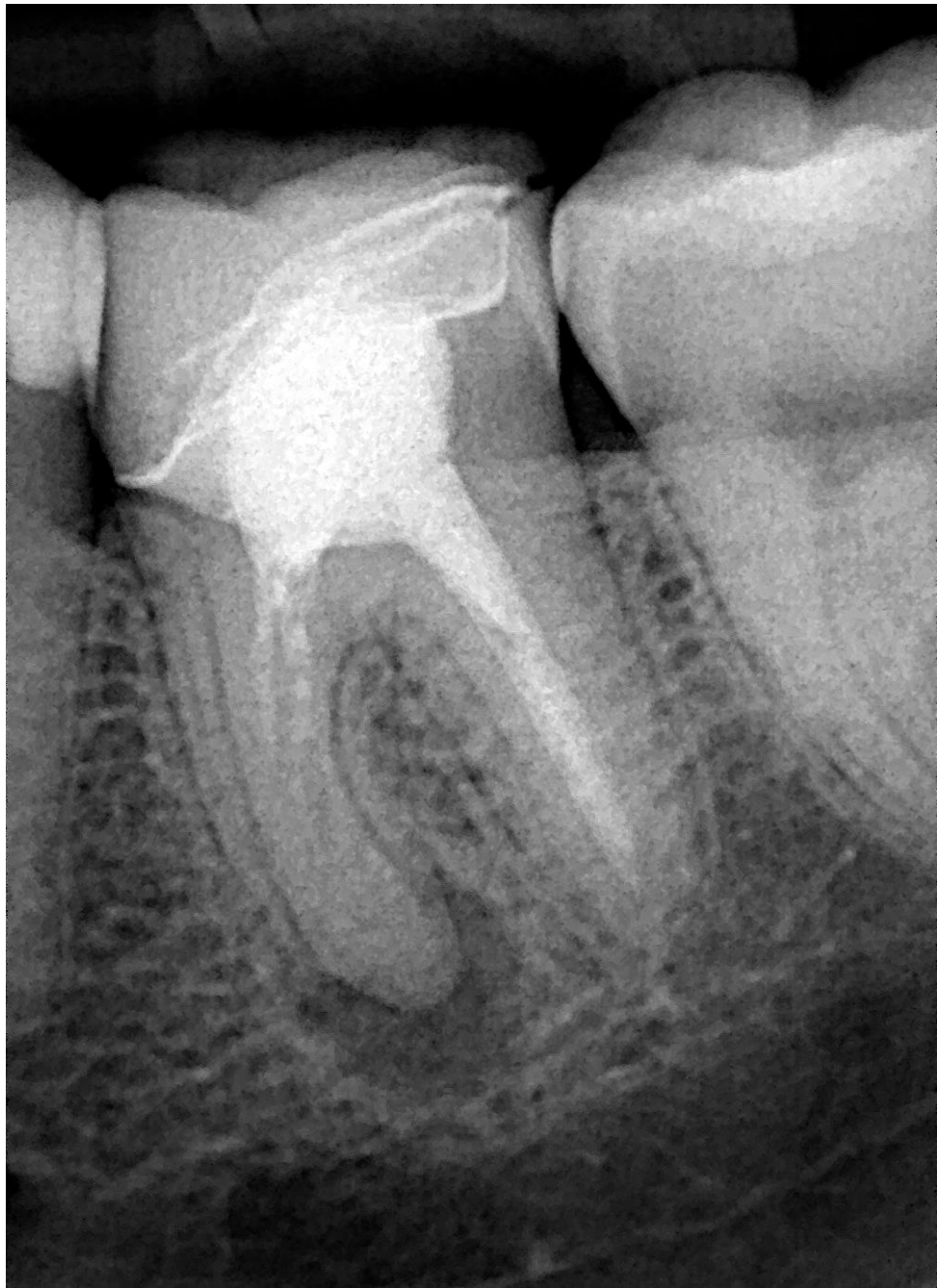
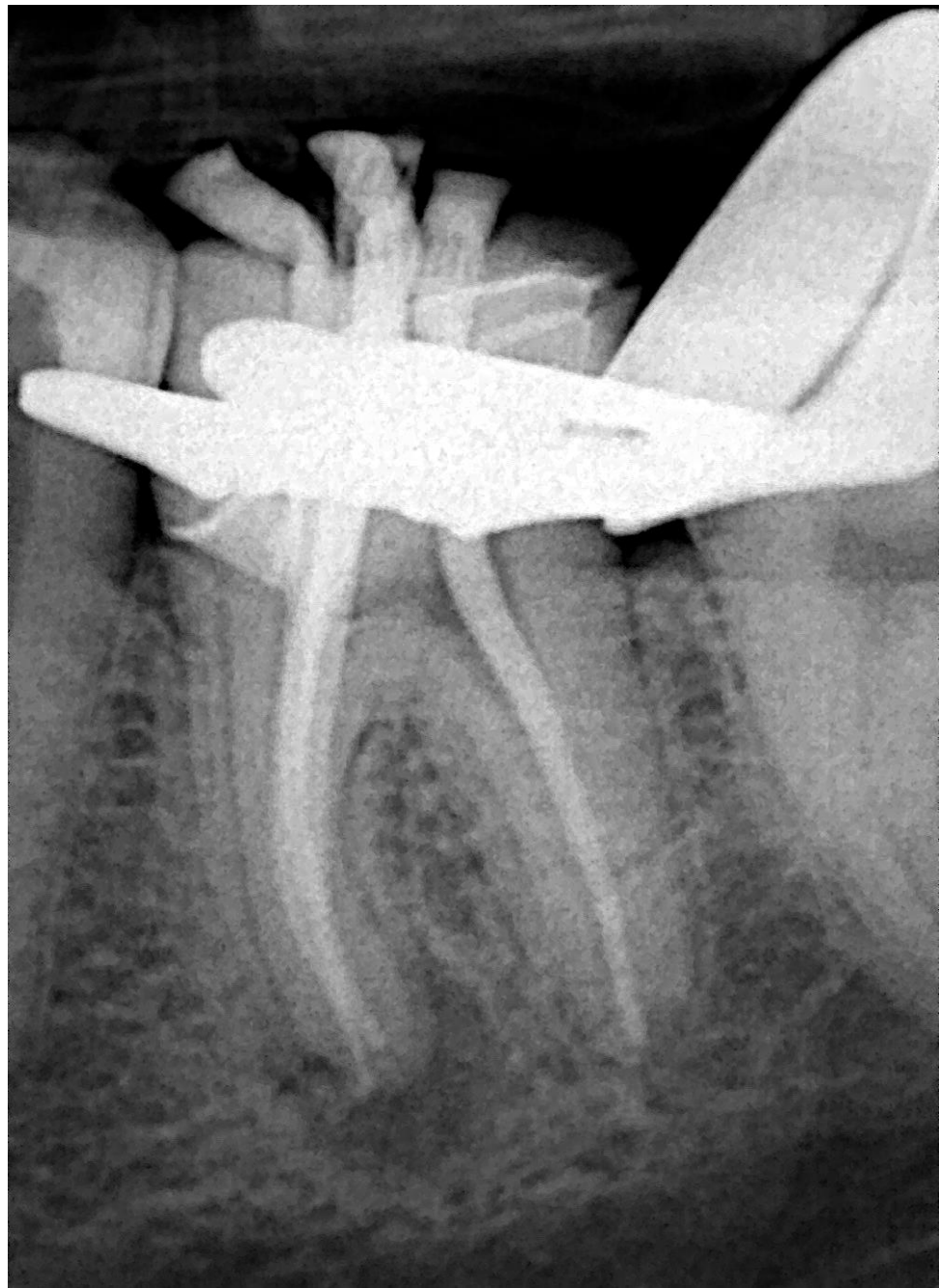
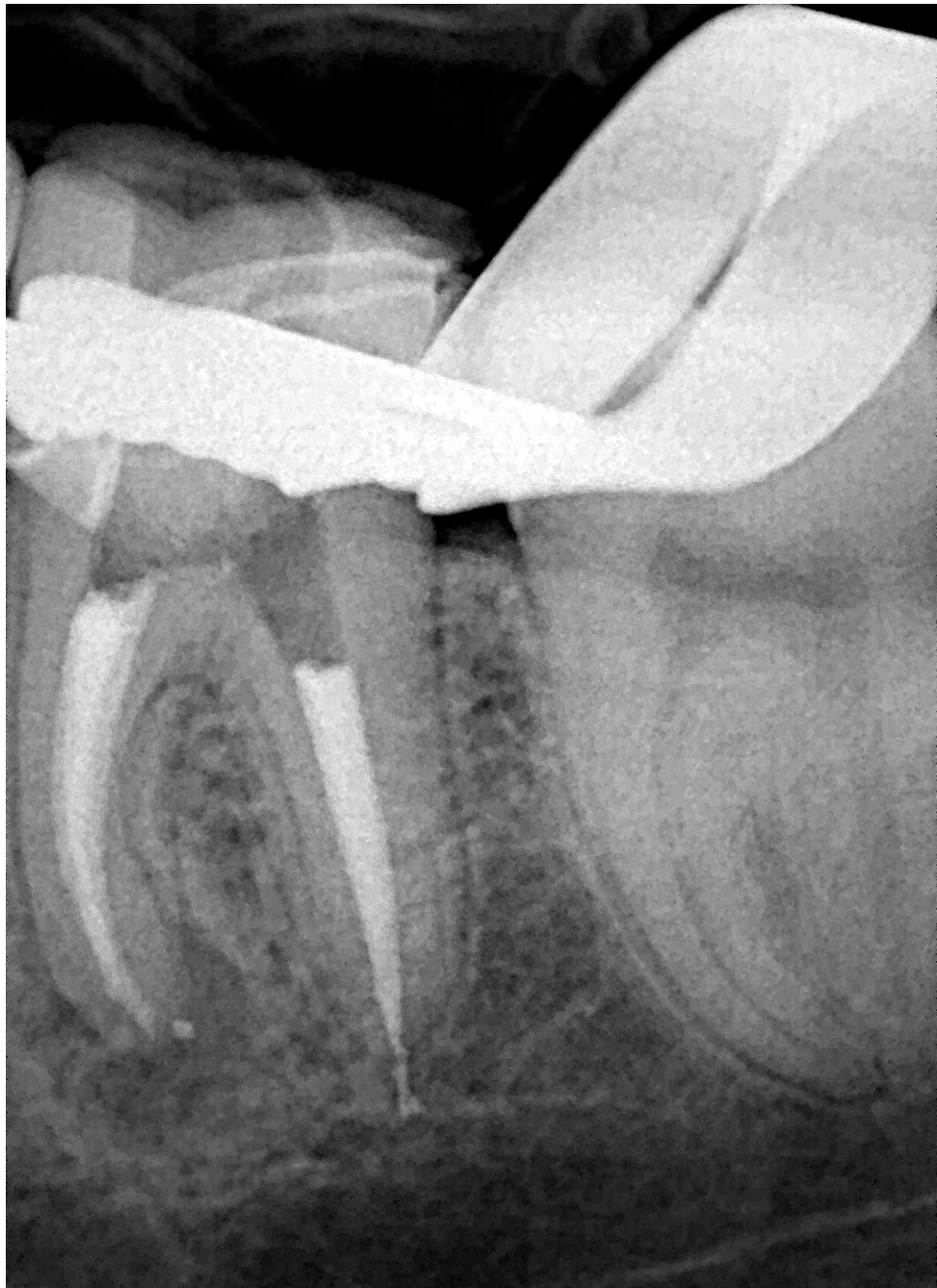
GO-TAPER RETREATMENT
DENTE 46
RITRATTAMENTO



Radiografía preoperatoria



Radiografía de cono maestro



Radiografia postoperatoria